




Arab Journal of Urology

(Official Journal of the Arab Association of Urology)

www.sciencedirect.com



STONES / ENDOUROLOGY ORIGINAL ARTICLE

Multislice computed tomography vs. intravenous urography for planning supine percutaneous nephrolithotomy: A randomised clinical trial

Osama A. El-Wahab ^a, Magdy A. El-Tabey ^{a,*}, Ehab El-Barky ^a,
Shabieb A. El-Baky ^a, Adel El-Falah ^a, Medhat Refaat ^b

^a Department of Urology, Benha Faculty of Medicine, Benha, Egypt

^b Department of Radiology, Benha Faculty of Medicine, Benha, Egypt

Received 24 July 2013, Received in revised form 10 November 2013, Accepted 14 November 2013

KEYWORDS

Supine PCNL;
IVU;
Multislice CT;
Stone

ABBREVIATIONS

PCNL, percutaneous
nephrolithotomy;
US, ultrasonography;
BMI, body mass index

Abstract Objective: To compare the outcome of treatment planning using multi-slice computed tomography (CT) or intravenous urography (IVU) for supine percutaneous nephrolithotomy (PCNL).

Patients and methods: The study included 60 patients with renal stones, all treated by supine PCNL, between March 2011 and October 2012. The patients were divided randomly into two equal groups; in group 1 30 patients had the PCNL access planned based on IVU findings, and in group 2 the PCNL access was planned based on multislice CT images. All patients were suitable for PCNL, based on a plain abdominal film and ultrasonography, and with a body mass index of $< 30 \text{ kg/m}^2$. The exclusion criteria were renal anomalies and bleeding diathesis. All data from both groups for the mean time taken to gain percutaneous access, operative duration, fluoroscopic time, access difficulty, stone-free rate and intraoperative morbidity were collected and analysed statistically.

Results: The mean (SD) time taken to gain percutaneous access was longer in group 1 than group 2, at 22.2 (1.76) vs. 13.1 (1.62) min ($P < 0.001$), as were the operative duration, at 81.9 (14.9) vs. 58.8 (7.6) min ($P < 0.001$), and fluoroscopic

* Corresponding author. Tel.: +20 111805359; fax: +20 502269525.

E-mail address: prof.dr.mbaier@hotmail.com (M.A. El-Tabey).

Peer review under responsibility of Arab Association of Urology.



Production and hosting by Elsevier

time, at 3.5 (1.7) vs. 2.2 (1.3) min ($P = 0.002$). In group 1 there were four cases (13%) in which there were difficulties in establishing percutaneous access, while in group 2 there were none ($P = 0.003$). There was intraoperative morbidity in three patients (10%) in group 1 and two (7%) in group 2.

Conclusion: Multislice CT is a safer, more accurate and noninvasive imaging technique than IVU for mapping the pelvicalyceal system. It saves time and is essential in choosing the optimal percutaneous access into the pelvicalyceal system for a safe and successful PCNL.

© 2014 Production and hosting by Elsevier B.V. on behalf of Arab Association of Urology.

Introduction

Percutaneous nephrolithotomy (PCNL) is considered to be an established effective and safe technique for treating patients with renal stones. This is because of the extensive advances in instrumentation, radiological imaging techniques, and the cumulative experience of urologists in this field [1]. It is difficult for the traditional abdominal plain film and IVU to provide sufficient information for a safe percutaneous approach, while multislice CT can reproducibly and accurately map the pelvicalyceal system, as such information is essential in choosing the optimal percutaneous approach into the pelvicalyceal system for a safe and successful PCNL [2]. Gaining needle access to the desired calyx in the renal collecting system is an essential first step for a successful percutaneous renal procedure [3].

Multislice CT is a relatively new diagnostic imaging method, providing a comprehensive evaluation of the upper and lower urinary tract, and has started to replace other imaging techniques, especially IVU. The technique uses a multidetector CT with thin-slice imaging, intravenous administration of a contrast medium, and imaging in the arterial, corticomedullary and excretory phases. Two- and three-dimensional images of the targeted organs can then be obtained through digital image reconstruction [4,5].

Supine PCNL offers potential advantages, including better urethral access with an easy ability to perform lower urinary tract endoscopy during the procedure, better control of the airway, a significantly faster operation, and less postoperative pain and medication, thus allowing for early ambulation and avoiding the complications of general anaesthesia [6]. The aim of the present study was to compare multislice CT and IVU for planning the access before PCNL.

Patients and methods

This prospective randomised clinical study, conducted between March 2011 and October 2012, included 60 patients with renal stone disease who fulfilled the inclusion

and exclusion criteria. All the patients were treated with PCNL while supine. They were divided into two equal groups; for patients in group 1 the PCNL access was planned based on the IVU, and in group 2 the PCNL access was planned based on multislice CT.

To be included, patients had to be suitable for PCNL, based on a plain abdominal film and ultrasonography (US), with a body mass index (BMI) of $< 30 \text{ kg/m}^2$. Patients were excluded if they had renal anomalies, bleeding diathesis, dye sensitivity, and if they were retrocolonic cases diagnosed by multislice CT. The patients were assessed using routine laboratory and radiological investigations, i.e., a complete urine analysis with culture and sensitivity test if needed, serum creatinine level, a complete blood count, coagulation profile, liver function tests and fasting blood sugar, and by a plain abdominal film and US.

In group 1 the IVU comprised a plain abdominal film before administering 50 mL of an intravenous nonionic contrast medium, followed by an anteroposterior view at 5 min, anteroposterior and bilateral oblique views at 15 min, an anteroposterior view at 30 min, and a postvoiding view. Further delayed images were taken if necessary. In group 2, on the day before surgery the patient underwent multislice CT with no contrast medium, as follows: with the patient standing, a line was drawn on the skin of the mid-axillary line and a second on the posterior axillary line, using a waterproof pen (Fig. 1). Two ureteric catheters were placed on each line, which were then fixed to the patient by adhesive plaster (Fig. 2). The patient was then placed on the multislice CT scanner in the same position as during surgery, i.e., supine, and with a water bag ($\approx 3 \text{ L}$) placed under the lower part of the abdomen, to simulate the anatomical relationship during surgery (Fig. 3).

All CT examinations were done using a 16-row multidetector CT scanner (Activion 16; Toshiba Medical Systems, Japan). Images were then reconstructed, focusing on the anatomical details such as ribs, and the abdominal organs, such as the colon, liver, spleen, renal parenchyma, collecting system and stones. The ureteric catheter marker, which appeared on CT as point on

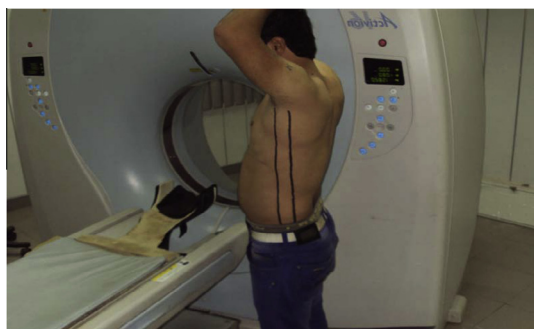

Figure 1 The two lines drawn on the patient represent the mid- and posterior axillary lines.

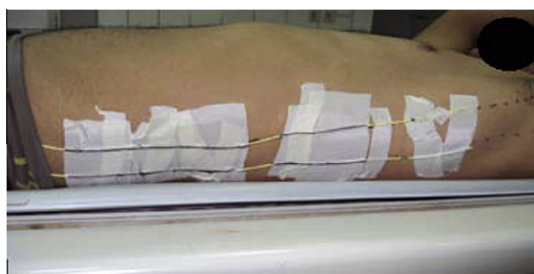

Figure 2 Two ureteric catheters were fixed on both axillary lines.



Figure 3 A water bag was placed under the lower part of the abdomen.

the skin, helped in choosing the best site of skin entry in relation to the stones (from the posterior axillary line or mid-axillary line, or in between). All these data helped in the preoperative planning for selecting the most accurate and safest access site for PCNL (Fig. 4).

Fully informed written consent was obtained from all patients; the complications of PCNL, and the possibility of conversion to open surgery, should it be necessary, were also discussed with the patient.

This study was approved by the Urology Department and by the local ethics and research committee of our Faculty of Medicine. All the patients were operated upon by the same urology team using single-session PCNL, with the patient supine.

The clinical data from both groups were recorded on a report form. These data were tabulated and analysed using a standard statistical package. Descriptive statis-

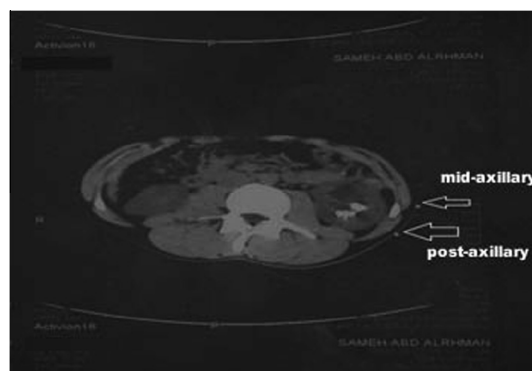


Figure 4 The small arrow refers to the mid-axillary line, while the large arrow shows the posterior axillary line.

tics were calculated as the mean (SD) for quantitative data, and the frequency and distribution for qualitative data. For the statistical comparison between the groups, the significance of differences was tested using Student's *t*-test to compare mean of two groups, the *Z*-test to compare the proportion between groups for qualitative data, or the chi-squared test for inter-group comparisons of categorical data. In all tests, $P < 0.05$ was considered to indicate statistical significance, and $P < 0.01$ as highly significant. A sensitivity analysis suggested a minimum sample size of 51, which was less than the sample size of 60 patients.

Results

The baseline characteristics of the patients in the two groups is shown in Table 1. The time taken to gain percutaneous access was longer in group 1 than group 2 ($P < 0.001$; Table 1), as was the operative time ($P < 0.001$) and fluoroscopy time ($P = 0.002$). In group 1 the puncture was upper calyceal in no patient, middle calyceal in four, and lower calyceal in most (23), with multiple punctures in three. In group 2, the puncture was upper calyceal in no patient, middle calyceal in two, lower calyceal in most (24) and multiple in four. There was no statistically significant difference between the groups in the frequency and types of puncture.

Intraoperative morbidity comprised three patients in group 1 (10%), who had significant bleeding requiring a blood transfusion (grade 2, Clavien system), while in group 2, two patients (7%) had significant bleeding and required a blood transfusion. This was directly related to stone size, duration of the PCNL and the creation of multiple tracts. There were no perforations or visceral injuries in both groups during the study; three patients with a retro-renal colon were detected by multislice CT and excluded from the study because of the possible risk of organ injury during PCNL. In four patients (13%) in group 1 there was difficulty in establishing percutaneous access (grade 1, Clavien system), while in group 2 there were no such patients ($P = 0.003$; Table 1).

Table 1 Characteristics of the patients and stones in both groups, the operative variables, and morbidity.

Variable	Group 1 (30)	Group 2 (30)	P
<i>Mean (SD):</i>			
Age (years)	32.3 (11.9)	34.7 (9.4)	0.39
BMI, kg/m ²	26.2 (2.4)	25.1 (3.9)	0.22
<i>Sex, n (%)</i>			
Male	16 (53)	17 (57)	0.8
Female	14 (47)	13 (43)	
Previous renal surgery, n (%)	7 (23)	5 (17)	0.52
<i>Stone side, n (%)</i>			
Right	16 (53)	14 (47)	0.61
Left	14 (47)	16 (53)	
<i>Stone opacity, n (%)</i>			
Radio-opaque	27 (90)	26 (87)	0.67
Radiolucent	3 (10)	4 (13)	
<i>Stone location, n (%)</i>			
Upper calyx	1 (3)	1 (3)	0.84
Middle calyx	2 (7)	3 (10)	
Lower calyx	21 (70)	22 (73)	
Pelvic	2 (7)	1 (3)	
Multiple	4 (13)	3 (10)	
<i>Mean (SD) time (min) for:</i>			
Tract access	22.2 (1.76)	13.1 (1.62)	<0.001
Operation	81.9 (14.9)	58.8 (7.6)	<0.001
Fluoroscopy	3.5 (1.7)	2.2 (1.3)	0.002
<i>Morbidity, n (%)</i>			
Intraoperative			
Access difficulty	4 (13)	0	0.03
Bleeding	3 (10)	2 (7)	0.64
Postoperative			
Fever > 38 °C	4 (13)	5 (17)	0.72
Urinary leakage	1 (3)	2 (7)	0.55
Haematuria	2 (7)	2 (7)	1.0
Residual stone	5 (17)	4 (13)	0.7

The mean (SD) decrease in haemoglobin level in group 1 was 1.56 (0.27) g/dL, vs. 1.53 (0.21) g/dL in group 2. There was postoperative fever in four patients (13%) in group 1 and in five (17%) in group 2 (grade 1, Clavien system); these patients were treated with anti-pyretics. There was prolonged leakage in one (3%) patient in group 1 and in two (7%) in group 2 after removing the nephrostomy tube (grade 1, Clavien system). There was haematuria in two (7%) patients in group 1 and two (7%) in group 2 (grade 1, Clavien system). There was no statistically significant difference between the groups in postoperative complication rates (Table 1). The stone-free rate of group 2 was 87% (26 patients) but there were residual stones (> 4 mm in diameter) in four who required a second PCNL, while the stone-free rate of group 1 was 83% (25 patients), with five having residual stones; four of them required a second PCNL, while the fifth patient underwent ESWL, as the stone was ≈1 cm in diameter and in a different calyx. There was no statistically significant difference between the groups (Table 1) in the outcome. There

was no considerable difference between the techniques in cost.

Discussion

Although PCNL was first described less than three decades ago, it has developed into a particularly effective procedure that is commonly used to treat patients with large or otherwise complex calculus disease. For the urologist to achieve an optimal outcome for patients undergoing PCNL, it is mandatory to give meticulous attention to patient selection criteria, preoperative planning details, intraoperative surgical techniques, and postoperative management decisions. It has been viewed as mandatory to evaluate the patient's collecting system with either IVU or retrograde pyelography. Recently, more patients have been initially evaluated with multislice CT [7–9]. PCNL is still a challenging procedure that requires an experienced and careful surgeon who is aware of the pitfalls. Patient selection, preoperative preparation and postoperative care must be profession-

ally handled to supply immediate care in case of unexpected problems [10].

In the present study, 60 patients with stone disease were enrolled and were suitable for PCNL, all with the patient supine, as this position offers potential advantages, including less handling of patients, better urethral access, easier ability to use lower urinary tract endoscopy, and more rapid control of the airway, especially in patients with compromised cardiopulmonary function and morbid obesity, as advocated by Falahatkar et al. [6].

The present study showed that the mean time taken to gain the percutaneous access, the operative duration and the time of fluoroscopic exposure were all shorter in group 2, where planning was based on multislice CT, and with four cases of difficulty in gaining access in group 1, based on IVU. In the present study, the mean time taken to gain percutaneous access was longer in group 1 than group 2 (Table 1; $P < 0.001$), which is in agreement with the findings of Ghani et al. [11], where the IVU group required 18.2 min to gain percutaneous access, vs. 15.5 min in the multislice CT group. The operative duration was also statistically longer in group 1 than group 2 (Table 1; $P < 0.001$). However, these results were not comparable with those of Eid et al. [12], as in their study of PCNL in kidneys with rotation and fusion anomalies, the mean operative duration was comparable in both groups. Wang [13] reported a longer mean operative duration (112.5 min) in his study of PCNL in 71 cases of renal stones, based on planning by CT urography. The present fluoroscopic time was also longer in group 1 than group 2 (Table 1; $P = 0.002$). There was significant intraoperative bleeding requiring a blood transfusion in three patients (10%) in group 1, and two (7%) in group 2. Bleeding was related to stone size, duration of PCNL and the creation of multiple tracts.

The decline in haemoglobin level was not statistically significantly different between the groups, which is comparable to the results of Ghani et al. [11], in which the decline in haemoglobin in the IVU group was 1.56 g/dL and was 1.6 g/dL in the multislice CT group. However, our findings are at variance with those of Eid et al. [12], who found that the decline in haemoglobin was significantly less in the CT group than in the IVU group.

The prolonged leakage and haematuria rates were similar in both groups, so the postoperative complications were comparable, with no significant statistical differences, which is in agreement with the study of Ghani et al. [11]. However, three patients with a retrorenal colon were detected by multislice CT and excluded from the study. As Juan et al. [14] stated, any organ adjacent to the kidney can be injured during PCNL and these anatomical abnormalities cannot be visualised by IVU or US. Hence, as multislice CT can show a cross-sectional anatomical region, it can facilitate the accurate

identification of adjacent structures to avoid their injury during PCNL. Also, Chalasani et al. [5] suggested that patients at risk of colonic injury during PCNL should be assessed by CT before the procedure, as this helps in planning access sites and avoiding injury.

In the present study the stone-free rate of both groups, and the incidence of residual stones (> 4 mm in diameter), was not significantly different, which is comparable to the results of Ghani et al. [11]. In the study by Eid et al. [12] the stone-free rate was better in the CT group (90%) than in the IVU group (77%). Also, our results are comparable to those of Wang [13], reporting 71 cases of PCNL based on CT urography and a stone-free rate of 86%. The present study confirmed the superiority of multislice CT for planning PCNL in supine patients, not only for the efficacy but also for its safety compared to IVU.

The limitations of the present study include the few patients enrolled, that patients had a BMI of < 30 kg/m², the relatively small stone burden, and the few percutaneous accesses through the upper or middle calyx. Based on our experience, we recommended using multislice CT before supine PCNL to obtain easy, direct and safe access, and to improve stone clearance and reduce the complication rate.

In conclusion, multislice CT is a more accurate method than IVU for predicting the target site for percutaneous access in an easy and safe manner, with no increase in radiation exposure, and saving time; hence, it should be considered as a standard tool for planning PCNL.

Conflict of interest

None declared.

Funding

This study was not funded.

References

- [1] Rana AM, Bhojwani JP, Junejo NN, Das Bhagia S. Tubeless PCNL with patients in supine position: procedure for all seasons?—with comprehensive technique. *Urology* 2008;71:581–5.
- [2] Bazardzonovic M, Manojlovic Z, Sulejmanovic A, Jagodic S, Durakovic H, Praso H. CT urography and 3D reformatting in planning of percutaneous nephrolithotomy. *Eur. Urol.* 2008;7(Suppl.):189.
- [3] Bilen CY, Koçak B, Kitirci G, Danaci M, Sarikaya S. Simple trigonometry on computed tomography helps in planning renal access. *J. Urol.* 2007;70:242–5.
- [4] Georgiopoulos I, Tsagkatakis E, Nikolakakos F, Neofitou G, Fragioudaki I, Laspas F, et al. CT urography: clinical indications, limitations and radiation dose: a proposed approach. *Eur. Urol.* 2009;8(Suppl.):652.
- [5] Chalasani V, Bissoon D, Bhuvanagir AK, Mizzi A, Dunn IB. Should PCNL patients have a CT in the prone position preoperatively? *Can. J. Urol.* 2010;17:5082–6.

- [6] Falahatkar S, Farzan A, Allahkhah A. Is complete supine percutaneous nephrolithotomy feasible in all patients? *Urol. Res.* 2011;**39**:99–104.
- [7] Matlaga BR, Kim SC, Watkins SL, Kuo RL, Munch LC, Lingeman JE. Percutaneous nephrolithotomy for ectopic kidneys: over, around, or through. *Urology* 2006;**67**:513–7.
- [8] Ganpule P, Desai R. What's new in percutaneous nephrolithotomy? *Arab. J. Urol.* 2012;**10**:317–23.
- [9] Roy OP, Angle JF, Jenkins AD, Schenkman NS. Cone beam computed tomography for percutaneous nephrolithotomy. Initial evaluation of a new technology. *J. Endourol.* 2012;**26**:814–8.
- [10] Ritter M, Krombach P, Michel M. Percutaneous stone removal. *Eur. Urol.* 2011;**10**(Suppl.):433.
- [11] Ghani KR, Patel U, Anson K. Computed tomography for percutaneous renal access. *J. Endourol.* 2009;**23**:1633–9.
- [12] Eid N, Abdeldaeim H, Hamdy S, Sakr M, Zahran A, Marzouk E. Percutaneous nephrolithotomy in kidneys with rotation and fusion anomalies: CT versus IVU planned accesses. *Urology* 2009;**74**(Suppl.):S75.
- [13] Wang D. 3-Dimensional reconstruction of 16-slice spiral computed tomography urography (CTU) in percutaneous nephrolithotomy (PCNL) in treatment of complex kidney stones. *Urology* 2009;**74**(Suppl.):S339.
- [14] Juan YS, Huang CH, Chuang SM, Shen JT, Li CC, Wang CJ, et al. Colon perforation: a rare complication during percutaneous nephrolithotomy. *Kaohsiung J. Med. Sci.* 2006;**22**:99–102.